

Emotion comprehension in the temporal variant of frontotemporal dementia

Howard J. Rosen,^{1,2} Richard J. Perry,^{1,2} Jennifer Murphy,^{1,2} Joel H. Kramer,^{1,2} Paula Mychack,^{1,2} Norbert Schuff,^{3,5} Michael Weiner,^{1,3,5} Robert W. Levenson⁴ and Bruce L. Miller^{1,2}

¹Department of Neurology, ²Memory and Aging Center, ³Department of Radiology, University of California at San Francisco, ⁴Department of Psychology, University of California at Berkeley and ⁵San Francisco Veterans Affairs Hospital Magnetic Resonance Imaging Unit, USA

Correspondence to: Howard Rosen, MD, Department of Neurology, University of California at San Francisco, Memory and Aging Center, 350 Parnassus Avenue, Suite 800, Box 1207, San Francisco, CA 94143-1207 USA
E-mail: howie@itsa.ucsf.edu

Summary

Frontotemporal dementia (FTD) is a neurodegenerative disease characterized by behavioural disorders that suggest abnormalities of emotional processing. Patients with the temporal variant of FTD (tvFTD) are particularly at risk for developing deficits in emotional processing secondary to atrophy in the amygdala, anterior temporal cortex (ATC) and orbital frontal cortex (OFC), structures that are components of the brain's emotional processing systems. In addition, previous studies have suggested that predominantly right, as opposed to left temporal atrophy is more likely to be associated with behavioural and emotional impairments in tvFTD. However, emotional processing has never been assessed directly in this group. We examined one aspect of emotional processing, namely the comprehension of facial expressions of emotion (emotional comprehension) in nine individuals with tvFTD, and correlated performance on this measure with atrophy (as measured from T₁-weighted MRI scans by region of interest analysis) in the amygdala, ATC and OFC. Compared with age-matched controls, the tvFTD group was impaired in emotional comprehension, with more severe

impairment for emotions with negative valence, including sadness, anger and fear, than for happiness. Emotional comprehension was correlated with atrophy in the right amygdala and the right OFC, and not with atrophy in other structures. When individual profiles of amygdala atrophy were examined across patients and compared with control values, right amygdala atrophy was always accompanied by left amygdala atrophy, whereas patients with volume loss in the left amygdala could have normal or decreased right amygdala volumes. Thus, emotional comprehension appeared to be most impaired when bilateral amygdala atrophy was present, and was not associated with the degree of left amygdala atrophy. Our data indicate that tvFTD is associated with impairments in emotional processing that may underlie some behavioural problems in this disorder, and that the emergence of such deficits depends on the specific pattern of anatomical injury. These results have implications both for the clinical presentation in tvFTD patients and for the study of the neuroanatomical basis of emotion.

Keywords: frontotemporal dementia; emotion; amygdala; temporal lobe; MRI

Abbreviations: ATC = anterior temporal cortex; FAB = Florida Affect Battery; FTD = frontotemporal dementia; MMSE = Mini-Mental State Examination; OFC = orbital frontal cortex; tvFTD = temporal variant of frontotemporal dementia

Introduction

Frontotemporal dementia (FTD) is a neurodegenerative disorder that is localized primarily to the frontal lobes and the anterior portions of the temporal lobes. In contrast to other neurodegenerative diseases such as Alzheimer's disease, where memory is usually the first deficit, FTD is associated with early behavioural abnormalities, including apathy, disinhibition, obsessive and compulsive behaviours, emo-

tional blunting and loss of sympathy and empathy. These behavioural signs characteristically precede impairment in memory and are among the most reliable means of differentiating FTD from other disorders causing dementia (Miller *et al.*, 1997; Neary *et al.*, 1998). In one anatomical subtype of FTD, the degeneration appears to involve selectively, and often asymmetrically the amygdala and anterior temporal

lobes, as well as the posterior/medial portion of the orbital frontal cortex (OFC) (Edwards-Lee *et al.*, 1997; Mummery *et al.*, 1999; Chan *et al.*, 2001; Galton *et al.*, 2001; Rosen *et al.*, 2002). This subtype, called the temporal variant of FTD (tvFTD), serves as a powerful model for exploring the behavioural sequelae of slow, often asymmetric, right- or left-sided degeneration of the anterior temporal lobe and the amygdala.

To date, the behavioural deficits associated with amygdala, anterior temporal and orbital frontal damage in tvFTD have not yet been fully characterized. However, previous lesion and functional neuroimaging studies have indicated that the amygdala, anterior temporal and orbital frontal regions play a key role in the modulation of emotion, with the amygdala being especially important for the comprehension of negative emotions, particularly fear (Adolphs *et al.*, 1994, 1999; Hornak *et al.*, 1996; Schneider *et al.*, 1997; Scott *et al.*, 1997; Blair *et al.*, 1999; Anderson *et al.*, 2000; Gorno-Tempini *et al.*, 2001). Consistent with these observations, a recent study found that patients with tvFTD had impairments in the display of fear, although emotional processing was assessed through a questionnaire given to caregivers, and was not tested directly in the patients (Snowden *et al.*, 2001). Another study of FTD patients demonstrated impairment in the comprehension of disgust, fear and contempt, but not happiness. In that study, the clinical and anatomical subtypes (and thus the proportion of patients with tvFTD) were not specified and there was no specific attempt to control for visual perceptual abilities (Lavenex *et al.*, 1999). Given the pattern of anatomical injury associated with tvFTD and the central role of these structures in emotional processing, it is reasonable to hypothesize that direct assessment of emotional processing in patients with tvFTD would reveal deficits that may be the basis for some of their behavioural abnormalities.

Additionally, the asymmetric degeneration in tvFTD should facilitate a better understanding of how the right versus the left anterior temporal cortex (ATC) and amygdala contribute to behaviour. Clinical-anatomical studies have suggested that anatomical heterogeneity in tvFTD is associated with differences in emotional processing abilities across patients. While predominantly left temporal damage is associated with loss of semantic knowledge, predominantly right temporal damage is associated with behavioural abnormalities including irritability, bizarre alterations in dress, impulsiveness and decreased facial expression (Edwards-Lee *et al.*, 1997). Furthermore, a recent case study suggested that tvFTD patients with predominantly right temporal degeneration were particularly impaired in emotional comprehension, and showed more emotional blunting and loss of empathy than did patients with tvFTD involving predominantly the left temporal lobe (Perry *et al.*, 2001). This suggests that emotional processing abnormalities may only occur in tvFTD when the right hemisphere is significantly affected. The current study set out to explore this hypothesis.

The primary aims of this study were: (i) to examine emotional processing, specifically recognition of facial

expressions of emotion, or emotional comprehension, in tvFTD; and (ii) to investigate the relationship between these abilities and lateralized damage to anterior temporal and orbital frontal structures. We used the Florida Affect Battery (FAB) to assess emotional comprehension (Bowers *et al.*, 1992), and performance on this measure was correlated with lateralized cerebral volumes across subjects. Based on previous clinical and experimental observations, we hypothesized that tvFTD would be associated with impairment in emotional comprehension, in particular for emotions with negative valence, and that this deficit would be related to the degree of right, as opposed to left temporal involvement, specifically the degree of right amygdala involvement.

Methods

Subjects

Patients

Nine patients with tvFTD (six men, three women, mean age 66 ± 8.3 years) were recruited from among patients evaluated for dementia at the UCSF Memory and Aging Center. The diagnosis of tvFTD was made if patients met clinical criteria for FTD (Brun and Passant, 1996), and showed atrophy affecting predominantly the temporal lobes, as indicated by visual inspection of brain images. Additional clinical features, including empty speech and impairment in naming and word comprehension, were usually present as well. These clinical criteria are similar to those used in previous studies (Bozeat *et al.*, 2000; Perry and Hodges, 2000). All patients were evaluated initially by a neurologist (B.L.M. or H.J.R.), a nurse and a neuropsychologist to establish the pattern of cognitive and behavioural deficits. All patients also had MRI scanning as detailed below. Patients with a Mini-Mental State Examination (MMSE) score below 15 were excluded.

The neuropsychological evaluation consisted of tests designed to assess general intellectual function (MMSE; Folstein *et al.*, 1975); working memory (digit span backwards); verbal episodic memory (California Verbal Learning Test; Delis *et al.*, 2000); visual episodic memory (memory for details of a modified Rey-Osterrieth figure); visual-spatial function (copy of a modified Rey-Osterrieth figure); confrontational naming (15 items from the Boston Naming Test; Kaplan *et al.*, 1983); comprehension of syntactical structure, sentence repetition, phonemic (words beginning with the letter 'D'), semantic (animals) and non-verbal fluency (novel designs; Delis *et al.*, 2000); and visual-motor sequencing (a modified version of the 'Trails B' test; Reitan, 1958). Verbal memory scores were translated into scaled scores to compare the tvFTD group's performance on the 9-item short form of the test with the standard 16-item version administered to the controls.

Behavioural control subjects

Ten control subjects (four men, six women, mean age 60.3 ± 8.1 years) were recruited from among individuals

participating in ongoing research of normal ageing at the UCSF Memory and Aging Center. All control subjects had no history of neurological or psychiatric disorders, no evidence of neurological disease on examination and no evidence of impairment on neuropsychological testing.

Neuroimaging control subjects

Thirteen subjects (seven men, six women, mean age 66.8 ± 8.2 years) were chosen from among a group of subjects enrolled in ongoing neuroimaging research in the San Francisco Veterans Administration Hospital to match the patient group in age. All neuroimaging control subjects had no history of neurological or psychiatric disorders, and had no evidence of focal disease or subcortical white matter ischaemic changes on their MRI.

The study was approved by the UCSF Committee on Human Research. All subjects provided informed consent before participating.

Measurement of emotional comprehension

Emotional comprehension was evaluated using the FAB, which consists of multiple subtests for the assessment of the understanding of facial and vocal expressions of emotion (Bowers *et al.*, 1992). For this analysis, only the data on facial expressions were used. In each of the facial affect subtests, photographs of faces (all female), depicting one of five expressions: happiness, sadness, anger, fear or no emotion (neutral), are presented. Five subtests were administered.

(i) Facial identity discrimination

Two photographs of faces of individuals, both with a neutral expression and with the hair covered, are displayed on a card for each trial. Subjects are required to indicate whether the two faces on the card are of the same person or different people. Twenty trials are presented.

(ii) Facial emotion discrimination

Two photographs of faces of individuals, each with a different identity and facial expression, are displayed on a card for each trial. Subjects are required to indicate whether the two faces on the card are depicting the same or different emotions. Twenty trials are presented.

(iii) Facial emotion naming

A single photograph of the face of an individual is presented on a card during each trial. For each trial, a different facial expression of emotion is depicted. Subjects are required to name the emotion depicted in the photograph. Twenty trials are presented, with four trials of each emotion.

(iv) Facial emotion selection

Five photographs of faces of the same individual, each with a different facial expression, are displayed on a card for each

trial. Subjects are required to select the face depicting the emotion requested by the examiner. Twenty trials are presented, with four trials of each emotion.

(v) Facial emotion matching

Two cards are presented simultaneously for this trial: one with a single photograph of the face of an individual depicting a particular emotion, and the other with five photographs of faces of different individuals, each with a different facial expression. Subjects are required to choose the face on the second card depicting the emotion shown on the first card. Twenty trials are presented, with four trials of each emotion.

Acquisition of MRI and cerebral volumes

MRI scanning

MRI scans were obtained on a 1.5-T Magnetom VISION system (Siemens Inc., Iselin, NJ) equipped with a standard quadrature head coil. Structural MRI sequences included: (i) 2D FLASH MRI along three orthogonal directions, 3 mm thick slices, ~15 slices in each direction to obtain scout views of the brain for positioning subsequent MRI slices. (ii) A double spin echo sequence [repetition time/echo time 1/echo time 2 ($TR/TE_1/TE_2$) = 5000/20/80 ms] to obtain proton density and T_2 -weighted MRIs, 51 contiguous axial slices (3 mm) covering the entire brain and angulated -10° from the AC-PC line; 1.0×1.25 mm² in-plane resolution. (iii) Volumetric magnetization prepared rapid gradient echo MRI [MPRAGE, repetition time/echo time/inversion time ($TR/TE/TI$) = 10/4/300 ms] to obtain T_1 -weighted images of the entire brain, 15° flip angle, coronal orientation perpendicular to the double spin echo sequence, 1.0×1.0 mm² in-plane resolution and 1.5 mm slab thickness.

Tissue segmentation

Subject brains were first segmented into grey matter, white matter and CSF using previously described methods (Tanabe *et al.*, 1997). Briefly, the locally developed software uses simultaneously acquired proton density, T_2 -weighted and T_1 -weighted MRIs to classify tissues automatically into the three major tissue types. Further separation of cortical from subcortical grey matter, ventricular CSF from sulcal CSF, and normal white matter from white matter lesions was performed manually by a single trained operator.

Cerebral volume measurements

Volumes were obtained for four structures: frontal cortex, amygdala, ATC and posterior/medial OFC. For each region, the volumes were obtained separately in the right and left hemispheres. The choice of this specific portion of OFC was made based on previous work indicating that this is the region of OFC with the most significant atrophy in tvFTD

Table 1 Performance on select neuropsychological tests

Subtest	Controls	tvFTD
MMSE	29.7 (.5)	24.5 (2.1)**
Boston Naming Test -15 items	14.4 (1.1)	4.3 (3.0)**
Modified Rey Figure copy	16.3 (.5)	14.8 (4.0)
Modified Rey Figure 10 min delay	12.5 (3.7)	7.0 (5.7)*
Modified CVLT short delay ⁺	0.65 (0.7)	-1.7 (1.0)**
Modified CVLT long delay ⁺	0.8 (0.7)	-1.3 (1.1)**
Modified Trails B time	20.7 (8.1)	94.1 (28.3)**
Modified Trails B errors	0 (0)	1.4 (1.4)
Digits backwards	5.6 (0.7)	4.5 (1.3)

⁺Values expressed in Z scores; * $P < 0.05$ compared with controls; ** $P < 0.01$ compared with controls.

(Mummery *et al.*, 2000; Rosen *et al.*, 2002). In addition, studies in patients with lesions in this region have also demonstrated abnormal emotional reactivity in decision-making tasks (Bechara *et al.*, 1996), and this is the portion of the orbital frontal region that has been shown in animal studies to be most heavily connected with the amygdala (Carmichael and Price, 1995). The frontal lobes were circled in the axial plane directly on the segmented images, using co-registered T₁-weighted images as a guide. The central sulci and sylvian fissures were used as landmarks for the posterior border, while CSF defined the lateral, medial, superior and inferior surfaces. The amygdala was hand segmented on T₁-weighted coronal images. The anterior boundary of the amygdala was defined by the closure of the sylvian fissure (endorhinal sulcus). The medial and superior boundaries were defined by CSF medial to the temporal lobe with the extra requirement that no tissue be included superior to the endorhinal sulcus. The lateral boundary was defined by the grey-white border in the white matter of the temporal lobe. This approach is essentially the same as previous methods used to obtain amygdala volumes (Watson *et al.*, 1992). While the use of the CSF margin as the medial boundary includes portions of entorhinal cortex in the amygdala measurement, the separation between amygdala and entorhinal cortex medially can be very difficult, even at 1 mm resolution. The approach including all structures lateral to the CSF boundary ensures the reproducibility of the measurements. Likewise, the superior-lateral border of the amygdala can be difficult to separate from the adjacent striatum and claustrum. The approach of making the endorhinal sulcus the arbitrary superior border was used to increase reliability. The anterior temporal lobe was also segmented on coronal T₁-weighted images, with the posterior border being defined as the endorhinal sulcus, and all other borders being defined by CSF. The OFC was segmented on the coronal T₁-weighted images. For OFC, the posterior boundary was the first slice anterior to the optic chiasm, and the anterior boundary was the last slice on which temporal lobe could be seen (on either hemisphere, regardless of whether the right or left OFC was being measured). The superior boundary for OFC was the superior rostral sulcus, on the medial frontal surface, and the

lateral boundary was the first orbital sulcus lateral to olfactory sulcus. Inferiorly and medially, CSF borders the OFC. A binary image was created for ATC and OFC as outlined in the coronal plane, and superimposed on the segmented tissue image for that subject to obtain a grey matter volume for these structures (not required for amygdala because it is essentially all grey matter).

All regions of interest were corrected for differences in head size by normalizing the regional volume using the total intracranial volume, which is the sum of all tissue and fluid volumes measured inside the skull (obtained from the segmented image).

Reliability of volume measurements

To establish reliability, an experienced operator rated frontal, ATC, amygdala and OFC volumes from eight subjects (three Alzheimer's disease patients and five controls) twice, with ratings separated by at least 2 weeks (a total of 16 measures of each structure). Reliability (intraclass correlation coefficient; ICC) for amygdala volumes was 0.90, indicating that rater variability accounted for only 10% of the variance of the data. For the ATC, whole frontal and OFC cortical volumes, the ICC values were 0.99, 0.97 and 0.93, respectively.

Data analysis

Performance (percentage correct) was calculated for each subtest of the FAB. In addition, the percentage correct for each specific emotion was calculated and averaged across all subtests where a single emotion was tested on each trial (the 3rd, 4th and 5th subtests described above). Differences in neuropsychological performance, performance in specific emotions and regional cerebral volumes (corrected for total intracranial volume) were examined across groups using analysis of variance (ANOVA), Student's *t* tests and analysis of covariance (ANCOVA) where appropriate. The relationship between anatomy and emotional processing was investigated through the analysis of the correlations (Pearson's '*r*') between anatomical structures of interest and measures of emotional processing. Because our hypotheses only involved positive relationships (larger regional volumes, better emotional comprehension), a one-tailed level of significance was accepted for these correlations. For planned comparisons, *P* values were corrected for multiple comparisons using the Bonferroni correction.

Statistical analysis was accomplished using the SPSS software package (version 10.0.5 for Windows, SPSS Inc., Chicago, IL, USA).

Results

Basic neuropsychological and demographic data

The MMSE score was substantially lower in the tvFTD group when compared with controls (mean MMSE of 29.6 in

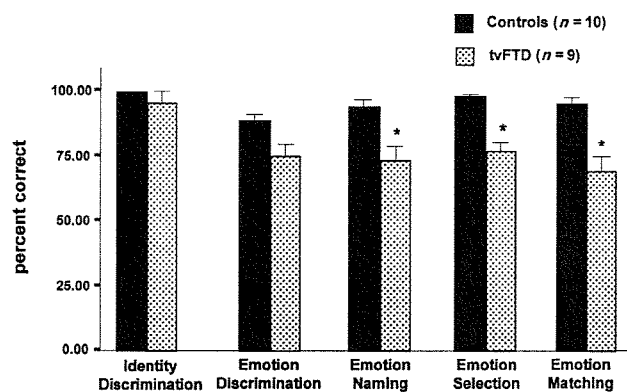


Fig. 1 Comparison of the performance of the control and tvFTD groups in each of the FAB subtests used. * $P < 0.05$ (corrected) compared with controls.

controls, 23.9 in tvFTD; see Table 1), as were scores for verbal memory [California Verbal Learning Test-short form (CVLT-SF) short and long delays] and visual memory (for details of the modified Rey–Osterrieth figure) and confrontation naming. No visuospatial processing deficits (Rey copy) were detected in the tvFTD group. The tvFTD group was also slower than controls on the Trails examination, but they did not make significantly more errors than controls and did not show a significant deficit in backwards digit span.

Performance on FAB subtests in tvFTD

Scores for the five subtests of the FAB in both groups were entered into a repeated measures analysis of variance (within-factor, subtest; between-factor, group). Main effects were observed for subtest [$F(4,68) = 8.58, P < 0.001$] and group [$F(1,17) = 14.213, P = 0.002$] with a group \times subtest interaction [$F(4,68) = 3.579, P = 0.01$]. Pairwise comparisons between the tvFTD and control groups revealed significant differences in emotional comprehension across groups on multiple subtests (Fig. 1, alpha of 0.01 after Bonferroni correction). These included facial emotion naming (controls, 94% correct; tvFTD, 73.3% correct; $P = 0.007$), facial emotion selection (controls, 98%; tvFTD, 75.9%; $P = 0.005$) and facial emotion matching (controls, 95.5%; tvFTD, 71.1%; $P = 0.005$). A smaller difference between groups in facial emotion discrimination did not survive multiple comparisons correction (controls, 88.5%; tvFTD, 74.4%; $P = 0.036$). There was no significant impairment in tvFTD on facial identity discrimination.

As delineated in Table 1, the tvFTD group was characterized by a reduced MMSE score when compared with the control group, and was significantly impaired in word retrieval, as indicated by the deficit in confrontational naming. The potential contribution of these deficits to emotional processing deficits was assessed using repeated measures ANCOVA (within-factor, subtest; between-factor, group) using the MMSE score and the Boston Naming Test score as covariates. All the previously observed effects

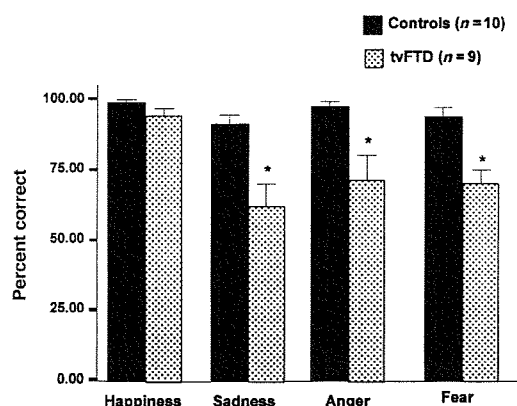


Fig. 2 Comparison of the performance of the control and tvFTD groups in each of the emotions tested on the FAB. Bars represent the mean percentage correct for each emotion across all trials where a single emotion was tested on each trial (emotion naming, emotion selection, emotion matching). * $P < 0.05$ (corrected) compared with controls.

persisted, including the main effects for subtest [$F(4,52) = 2.686, P < 0.041$] and group [$F(1,13) = 18.572, P < 0.001$], as well as the group \times subtest interaction [$F(4,52) = 4.021, P = 0.006$].

Comprehension of specific emotions in tvFTD

Scores for the four emotions assessed with the FAB were entered into a repeated measures ANOVA (within-factor, emotion; between-factor, group). Main effects were observed for emotion [$F(3,51) = 11.602, P < 0.001$] and group [$F(1,17) = 21.750, P < 0.001$] along with a group \times emotion interaction [$F(3,51) = 5.08, P = 0.004$]. Pairwise comparisons between the tvFTD and control groups revealed significant differences in emotional comprehension across groups on multiple emotions (Fig. 2, alpha of 0.01 after Bonferroni correction). These included sadness (controls, 90% correct; tvFTD correct, 60.2%; $P = 0.008$), anger (controls, 95%; tvFTD, 66.6%; $P = 0.005$) and fear (controls, 95.8%; tvFTD, 65.7%; $P = 0.005$). A smaller difference between groups in the comprehension of happiness (controls, 99.2%, tvFTD; 94.4%; $P = 0.094$) was not significant.

Regional volumes across groups

When compared directly with a control group, the tvFTD group showed significant reductions in the ATC (control mean 27.9 ± 3.76 ml; tvFTD mean 15.2 ± 4 ml; $P < 0.001$), amygdala (control mean 4.82 ± 0.95 ml; tvFTD mean 2.99 ± 0.53 ml; $P < 0.001$) and OFC (control mean 8.84 ± 1.24 ml; tvFTD mean 6.47 ± 0.85 ml; $P < 0.001$) regions (Fig. 3, alpha of 0.013 after Bonferroni correction). Volume loss in the frontal lobes overall was much lower in magnitude and was not significant after multiple comparisons correction (control mean 200.5 ± 10.72 ml; tvFTD mean 187.17 ± 14.19 ml; $P = 0.019$).

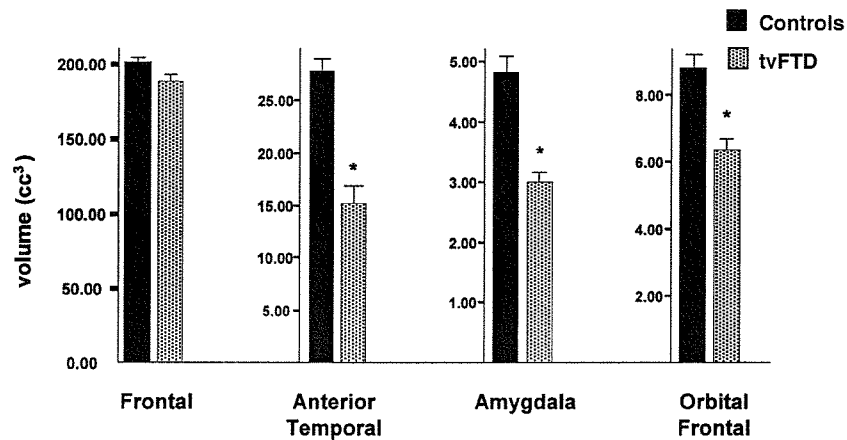


Fig. 3 Comparison of the right and left hemisphere combined volumes for the control and tvFTD groups in four regions of interest. * $P < 0.05$ (corrected) compared with controls.

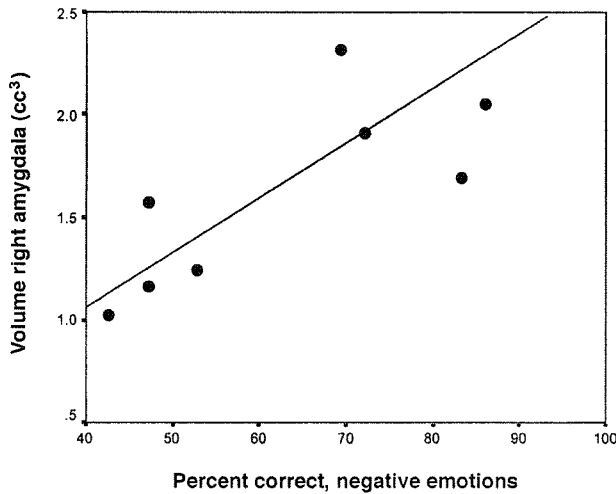


Fig. 4 Plot of right amygdala volume versus mean percentage correct for all negative emotions (same values used for Fig. 2) for each patient in the tvFTD group, with estimated regression line.

The correlation between regions in the tvFTD group was also examined. Right and left whole frontal volumes were highly positively correlated ($r = 0.82, P = 0.003$), as were right amygdala and right OFC volumes ($r = 0.76, P = 0.009$). There were no other significant positive correlations.

Correlation of regional volumes with emotion

Since the tvFTD group showed a deficit in emotional processing that was relatively specific to the comprehension of negative emotions, a composite measure of performance on sadness, anger and fear was created, and was correlated with volumes in the right and left hemisphere for the regions of significant volume loss in tvFTD (right and left amygdala, right and left ATC, and right and left OFC, alpha of 0.0083 after Bonferroni correction). A positive correlation was found between this measure and the volume in right amygdala

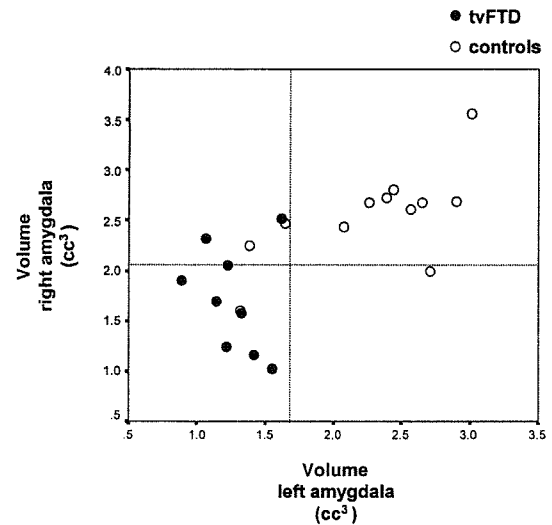


Fig. 5 Plot of right amygdala volume versus left amygdala volume for each patient in the tvFTD group and for each individual in the neuroimaging control group. Broken lines indicate the value for the control mean minus 1 SD.

($r = 0.77, P = 0.008$, Fig. 4). Comprehension for negative emotions was also correlated with volume in the right OFC, although the significance did not survive multiple comparisons correction ($r = 0.67, P = 0.024$).

To clarify the pattern of variance in amygdala volumes across patients, volumes of right versus left amygdala were plotted for each individual and examined in comparison with these values for the neuroimaging control group. The variance for the two amygdala volumes across patients was not equal (Fig. 5). While right amygdala volume was near normal in several tvFTD patients, left amygdala volume was substantially below the control mean (<1 SD) in every patient in the group. Thus, those patients who showed substantial reductions in right amygdala volume actually had bilateral amygdala atrophy.

Table 2 Correlations of emotional comprehension with regional volumes

	Right amygdala	Left amygdala	Right OFC	Left OFC	Right ATC	Left ATC
Negative emotions	0.77** (0.008)	-0.39 (0.151)	0.62* (0.038)	0.538 (0.067)	0.24 (0.266)	-0.365 (0.167)
Happiness	0.77* (0.007)	-0.26 (0.227)	0.83* (0.003)	0.29 (0.224)	0.24 (0.267)	-0.53 (0.073)
Sadness	0.76* (0.008)	-0.67 (0.025)	0.71* (0.016)	0.41 (0.136)	0.44 (0.116)	-0.25 (0.255)
Anger	0.41 (0.134)	-0.16 (0.340)	0.45 (0.110)	0.59* (0.048)	-0.01 (0.491)	-0.07 (0.430)
Fear	0.55 (0.064)	0.02 (0.483)	0.19 (0.310)	0.21 (0.292)	0.08 (0.421)	-0.54 (0.066)

*Correlation is significant to $P < 0.05$ (uncorrected, P value in parentheses). These r values are also highlighted in bold. Only positive correlations were hypothesized, so all P values are one-tailed; **Correlation is significant after multiple comparisons correction (alpha of 0.0083 after Bonferroni correction for correlation of negative emotion with six regions).

Although the primary hypothesis for this study specified a correlation between negative emotions and right hemisphere volumes, an exploratory analysis was also performed to investigate the relationship between specific emotions and regional cerebral volumes (Table 2). This analysis revealed a significant correlation (without corrections for multiple comparisons) between right amygdala volume and performance on happiness ($r = 0.77$, $P = 0.007$) and sadness ($r = 0.76$, $P = 0.008$), and a near significant correlation with performance on fear ($r = 0.55$, $P = 0.064$). Right OFC volume was correlated with performance on happiness ($r = 0.87$, $P = 0.001$) and sadness ($r = 0.8$, $P = 0.005$), and left OFC volume was correlated with performance on anger ($r = 0.59$, $P = 0.048$).

Discussion

The aim of the current analysis was to determine whether tvFTD is associated with deficits in emotional comprehension, and to examine the relationship between emotional comprehension abilities and regional cerebral atrophy in this patient population. Consistent with our hypothesis, the tvFTD group was significantly impaired in the understanding of facial expressions of emotion, and this deficit was not explained by a generalized visual perceptual deficit. As predicted, the impairment in emotional comprehension was more severe for emotions with negative valence (sadness, fear and anger) as opposed to positive valence (happiness). Furthermore, correlation analysis demonstrated significant relationships between emotional comprehension and regional volumes, with right amygdala and right OFC volumes being correlated with comprehension of negative emotions (in particular sadness), as well as happiness. Left OFC volume was correlated with the comprehension of anger. Below, we discuss these results in light of previous lesion and functional neuroimaging studies, and we address the implications for the clinical presentation of patients with tvFTD.

The pattern of emotional comprehension deficits in tvFTD is consistent with the results of prior studies in patients with focal cerebral injury and studies using functional imaging, which have suggested roles for the amygdala, anterior temporal and orbital frontal regions in the modulation of emotion (Adolphs *et al.*, 1994, 1999; Hornak *et al.*, 1996; Schneider *et al.*, 1997; Scott *et al.*, 1997; Blair *et al.*, 1999; Anderson *et al.*, 2000; Gorno-Tempini *et al.*, 2001). Prior

studies have suggested that unilateral amygdala damage is not associated with impairment in emotional comprehension (Adolphs *et al.*, 1995). Our results are consistent with these observations, in that unilateral left amygdala atrophy in our group was not associated with a deficit in emotional comprehension. Rather, emotional comprehension deficits in tvFTD were associated with bilateral amygdala damage. However, since no patients in this group presented with unilateral right amygdala atrophy, potential differences in impairment with right versus bilateral amygdala atrophy could not be addressed with these data. There were also some findings in this study that qualify previous results. Anterior temporal activation has been found during the processing of facial expressions of emotion (Blair *et al.*, 1999). However, in our tvFTD group, the presence of severe atrophy in the anterior temporal region did not account for any impairment in emotional processing. This suggests the possibility that the ATC may be involved in emotional face perception but not necessary for emotional comprehension.

With respect to the specific emotions affected by amygdala injury, previous studies have suggested that the comprehension of fear is most severely affected, although such patients also show less severe impairment in the interpretation of other negative emotions (Adolphs *et al.*, 1994, 1999; Scott *et al.*, 1997; Anderson *et al.*, 2000). Our tvFTD group showed emotional comprehension deficits across all negative emotions tested (fear, anger and sadness). Our use of a different battery of faces, specifically the FAB (Bowers *et al.*, 1992), as opposed to the Pictures of Facial Affect (Ekman and Friesen, 1975), makes direct comparison of our results with those of other studies difficult; however, more pervasive deficits in our group potentially could be attributable to more severe amygdala injury, or to the involvement of additional regions such as OFC (see below). Prior studies of patients with OFC injury have revealed deficits in emotional processing, although the variability in performance across emotions was not analysed (Hornak *et al.*, 1996). It is thus notable that emotional processing was highly correlated with right orbital frontal, as well as amygdala volume in our group.

Beyond the basic correlation of amygdala and OFC volume with emotional comprehension, the correlations between atrophy in specific regions and comprehension of specific emotions in our tvFTD group mirrored previous findings, particularly regarding negative emotions. In our tvFTD group,

right amygdala and right OFC atrophy were correlated with impaired interpretation of sadness, but not anger, and left OFC atrophy was correlated with impaired interpretation of anger, but not fear or sadness. A correlation between right amygdala volume and fear comprehension appeared to be present, but did not quite reach statistical significance. Prior human and animal studies have suggested that one emotion strongly linked with amygdala function is fear (Adolphs *et al.*, 1995; Fanelow and LeDoux, 1999). We would interpret the trend toward a correlation of amygdala volume with fear processing in tvFTD as generally consistent with this prior literature, with the absence of a significant correlation possibly reflecting the small number of subjects in the current study group. The role of the amygdala in emotional processing is not limited to fear processing. In functional imaging studies, amygdala activation has been found during the processing of sadness as well as fear, consistent with our findings (Morris *et al.*, 1996; Blair *et al.*, 1999). In addition, a recent study of patients who had undergone anterior temporal lobe removal for epilepsy demonstrated relatively selective impairment in the recognition of sadness and fear, as opposed to anger, in the right temporal removal group and not in the left temporal removal group (Anderson *et al.*, 2000). In contrast to the role of amygdala in the processing of fear and sadness, OFC activation has been elicited during the processing of anger, which is consistent with our finding of a correlation of left OFC volume and anger comprehension (Blair *et al.*, 1999). These results suggest that the combination of bilateral orbital frontal and amygdala injury in our tvFTD group may explain impairment on all three negative emotions tested.

Our findings regarding happiness deserve special comment. The fact that the deficit in the comprehension of happy faces was relatively small compared with other emotions in tvFTD is consistent with previous studies that failed to demonstrate a deficit in happiness comprehension in patients with amygdala damage. This relative sparing of happiness compared with negative emotions is consistent with psychophysical data indicating that happiness is easier to recognize than negative emotions (Hager and Ekman, 1979). However, our results indicate that, in patients with the most extensive amygdala and orbital frontal damage, comprehension of happiness is affected, suggesting that comprehension of happiness is processed by these systems, but is demonstrably impaired only when they are severely injured. Whether the residual abilities to process happy facial expressions are related to some preserved functions in the regions we measured, or related to the functions of other less injured regions cannot be answered presently. Also, because right amygdala and right orbital frontal volumes were correlated in our group, it is not possible to say whether this deficit is due to amygdala or orbital frontal injury, or both. Previous work demonstrating impairment in the recognition of happiness after right temporal lobectomy (Anderson *et al.*, 2000) and fMRI studies demonstrating activation of orbital frontal cortex during the explicit processing of happy faces (Gorno-Tempini *et al.*, 2001) support the hypothesis that orbital

frontal and right temporal structures are both involved in the comprehension of positive emotions.

Another issue raised by our findings concerns the hemispheric lateralization of the processing for positive emotions. Previous lesion and functional neuroimaging studies have suggested that the left amygdala and ATC are most closely linked with happiness (Schneider *et al.*, 1997; Canli, 1999). Yet, in our tvFTD group, left amygdala and anterior temporal atrophy did not relate to any deficit in the processing of happy faces, rather an impairment in the recognition of happiness was associated with the development of right amygdala and right orbital frontal injury. There are a number of potential explanations for this. One possibility is that, in patients with unilateral left amygdala atrophy, right-sided structures adapt to process positive emotions that usually are processed in the left hemisphere. On the other hand, those studies linking left hemisphere structures with positive emotions have mostly looked at emotional experience, rather than emotional comprehension (for a review see Canli, 1999). It is possible that the hemispheric lateralization for emotional comprehension is different from that for emotional reactivity. As noted above, prior studies do provide evidence for orbital frontal and right temporal involvement in the comprehension of positive emotions (Anderson *et al.*, 2000; Gorno-Tempini *et al.*, 2001).

The emotional processing deficits associated with amygdala and orbital frontal cortical injury in tvFTD may underlie some of the behavioural abnormalities seen in these patients. Many of the known deficits are potentially emotional in nature, including apathy, emotional blunting, and loss of sympathy and empathy. In addition to their implications regarding emotional processing, these findings suggest a potential anatomical explanation for the differing ways in which tvFTD patients present for medical evaluation. Previous work has suggested that patients with tvFTD and predominantly right temporal injury present with irritability, bizarre alterations in dress, impulsiveness and decreased facial expression (Edwards-Lee *et al.*, 1997). Our data suggest that such patients may actually present for medical evaluation when the degenerative process involves the amygdala bilaterally. While all patients in our group with right amygdala atrophy (and more impairment in emotional comprehension) had substantial volume loss in the amygdala bilaterally, patients with left amygdala atrophy could have normal or decreased amygdala volumes on the right. This may indicate a referral bias, such that patients in whom neural degeneration begins on the left side may present to the clinic at an earlier stage of disease, possibly due to the presence of language abnormalities that are apparent to the patient and family, and better insight on the part of the patient into his or her deficits (Reed *et al.*, 1993). Neural degeneration limited to the right temporal lobe and amygdala may be either asymptomatic or associated with behavioural symptoms that are difficult to recognize as neurological in origin, so that referral is delayed. Future work will need to focus on the specific symptoms associated with neural degeneration relatively limited to right temporal structures.

This study was limited by a number of factors, including the small sample size and the strong correlation between right amygdala and right orbital frontal cortical volumes. Although it is possible that right orbital frontal volume loss was related mechanistically to right amygdala volume loss (i.e. through loss of trophic support), larger studies may allow the dissociation of those functions specifically related to volume loss in each of these structures. Also, the correlation of emotional processing abilities with the particular regions chosen for this analysis does not rule out the possibility that other nearby (or distant) regions may also relate to some of these functions. With continued study of larger groups of subjects, it will be possible to use methods of image analysis that do not require *a priori* regions of interest, such as voxel-based morphometry, to investigate this possibility (Ashburner and Friston, 2000). Lastly, the identity discrimination task of the FAB may be too simple to detect subtle deficits in visual-spatial function that may have contributed to deficits in the comprehension of facial expressions of emotion. We think this is unlikely, because our visual construction task also did not demonstrate any significant impairment in the tvFTD group. In addition, previous studies of patients with focal right hemisphere injury using the FAB revealed deficits on the identity discrimination task, suggesting that it is sensitive to potential deficits associated with neurological disease (Bowers *et al.*, 1985). However, it will be useful for future work in these patients to incorporate more difficult face-processing tasks, as has been done by other groups (Sprengelmeyer *et al.*, 1996; Keane *et al.*, 2002).

These data strongly suggest that tvFTD is associated with a specific impairment in emotional comprehension, but more study will be required to understand the full extent of emotional deficits in these patients, and their anatomical basis. For instance, future studies will need to look at the generation of emotional reactions (e.g. how sad patients become when exposed to a sad film), which may be dissociated from the kind of emotional comprehension that we studied (Anderson and Phelps, 2000). Our data suggest that impairments in the comprehension of different emotions have different anatomical substrates (e.g. our finding that comprehension of fear and sadness are correlated with amygdala volume, and comprehension of anger is correlated with orbital frontal cortical volume). This will have to be addressed in larger groups of subjects.

Emotional processing in tvFTD will also need to be compared with that in the frontal variant of FTD (fvFTD). A recent study demonstrated impairment in recognition of facial and vocal expressions of emotion in six patients with fvFTD. In that study, impairments were present for negative emotions (sadness, anger and disgust), along with a less severe deficit for happiness (Keane *et al.*, 2002). A previous anatomical study demonstrated that tvFTD and fvFTD differ anatomically, but are both associated with atrophy in certain frontal regions, including the orbital frontal region (Rosen *et al.*, 2002). Thus, direct comparison of emotional processing in fvFTD and tvFTD, along with anatomical analysis, may shed

more light on the anatomical basis of emotional processing deficits in FTD.

Finally, it is hoped that increasing knowledge about FTD in the medical community will lead to earlier referral of patients with behavioural problems developing late in life. If this occurs, it is possible that the specific symptoms related to relatively focal right temporal disease will emerge. This could add to our knowledge about the neuroanatomical basis of emotion, and should lead to improved diagnosis of FTD.

Acknowledgements

We wish to thank Megan Bradley at the SFVA MR Unit for her help with image acquisition. This work was supported by the John Douglas French Foundation for Alzheimer's research, the McBean Foundation, the Sandler Foundation and the State of California.

References

- Adolphs R, Tranel D, Damasio H, Damasio A. Impaired recognition of emotion in facial expressions following bilateral damage to the human amygdala. *Nature* 1994; 372: 669–72.
- Adolphs R, Tranel D, Damasio H, Damasio AR. Fear and the human amygdala. *J Neurosci* 1995; 15: 5879–91.
- Adolphs R, Tranel D, Hamann S, Young AW, Calder AJ, Phelps EA, et al. Recognition of facial emotion in nine individuals with bilateral amygdala damage. *Neuropsychologia* 1999; 37: 1111–7.
- Anderson AK, Phelps EA. Expression without recognition: contributions of the human amygdala to emotional communication. *Psychol Sci* 2000; 11: 106–11.
- Anderson AK, Spencer DD, Fulbright RK, Phelps EA. Contribution of the anteromedial temporal lobes to the evaluation of facial emotion. *Neuropsychology* 2000; 14: 526–36.
- Ashburner J, Friston KJ. Voxel-based morphometry—the methods. [Review]. *Neuroimage* 2000; 11: 805–21.
- Bechara A, Tranel D, Damasio H, Damasio AR. Failure to respond autonomously to anticipated future outcomes following damage to prefrontal cortex. *Cereb Cortex* 1996; 6: 215–25.
- Blair RJ, Morris JS, Frith CD, Perrett DI, Dolan RJ. Dissociable neural responses to facial expressions of sadness and anger. *Brain* 1999; 122: 883–93.
- Bowers D, Bauer RM, Coslett HB, Heilman KM. Processing of faces by patients with unilateral hemisphere lesions: I. Dissociation between judgments of facial affect and facial identity. *Brain Cogn* 1985; 4: 258–72.
- Bowers D, Blonder L, Heilman K. The Florida Affect Battery. Gainesville (FL): Center for Neuropsychological Studies, University of Florida; 1992.
- Bozeat S, Gregory CA, Ralph MA, Hodges JR. Which neuropsychiatric and behavioural features distinguish frontal and temporal variants of frontotemporal dementia from Alzheimer's disease? *J Neurol Neurosurg Psychiatry* 2000; 69: 178–86.
- Brun A, Passant U. Frontal lobe degeneration of non-Alzheimer

- type: structural characteristics, diagnostic criteria and relation to other frontotemporal dementias. [Review]. *Acta Neurol Scand* 1996; Suppl 168: 28–30.
- Canli T. Hemispheric asymmetry in the experience of emotion: a perspective from functional imaging. *Neuroscientist* 1999; 5: 201–7.
- Carmichael ST, Price JL. Limbic connections of the orbital and medial prefrontal cortex in macaque monkeys. *J Comp Neurol* 1995; 363: 615–41.
- Chan D, Fox NC, Scahill RI, Crum WR, Whitwell JL, Leschziner G, et al. Patterns of temporal lobe atrophy in semantic dementia and Alzheimer's disease. *Ann Neurol* 2001; 49: 433–42.
- Delis DC, Lucas JA, Kopelman MD. Memory. In: Fogel BS, Schiffer RB, Rao SM, editors. *Synopsis of neuropsychiatry*. Philadelphia: Lippincott Williams & Wilkins; 2000. p. 169–91.
- Edwards-Lee T, Miller BL, Benson DF, Cummings JL, Russell GL, Boone K, et al. The temporal variant of frontotemporal dementia. *Brain* 1997; 120: 1027–40.
- Ekman P, Friesen WV. *Pictures of facial affect*. Palo Alto (CA): Consulting Psychologists Press; 1975.
- Fanselow MS, LeDoux JE. Why we think plasticity underlying Pavlovian fear conditioning occurs in the basolateral amygdala. [Review]. *Neuron* 1999; 23: 229–32.
- Folstein MF, Folstein SE, McHugh PR. 'Mini-mental state'. A practical method for grading the cognitive state of patients for the clinician. *J Psychiatr Res* 1975; 12: 189–98.
- Galton CJ, Patterson K, Graham K, Lambon-Ralph MA, Williams G, Antoun N, et al. Differing patterns of temporal atrophy in Alzheimer's disease and semantic dementia. *Neurology* 2001; 57: 216–25.
- Gorno-Tempini ML, Pradelli S, Serafini M, Pagnoni G, Baraldi P, Porro C, et al. Explicit and incidental facial expression processing: an fMRI study. *Neuroimage* 2001; 14: 465–73.
- Hager JC, Ekman P. Long-distance transmission of facial affect signals. *Ethol Sociobiol* 1979; 1: 77–92.
- Hornak J, Rolls ET, Wade D. Face and voice expression identification in patients with emotional and behavioural changes following ventral frontal lobe damage. *Neuropsychologia* 1996; 34: 247–61.
- Kaplan E, Goodglass H, Wintraub S. *Boston Naming Test*. Philadelphia: Lea and Febiger, 1983.
- Keane J, Calder AJ, Hodges JR, Young AW. Face and emotion processing in frontal variant frontotemporal dementia. *Neuropsychologia* 2002; 40: 655–65.
- Lavenex I, Pasquier F, Lebert F, Petit H, Van der Linden M. Perception of emotion in frontotemporal dementia and Alzheimer disease. *Alzheimer Dis Assoc Disord* 1999; 13: 96–101.
- Miller BL, Ikonte C, Ponton M, Levy M, Boone K, Darby A, et al. A study of the Lund-Manchester research criteria for frontotemporal dementia: clinical and single-photon emission CT correlations. *Neurology* 1997; 48: 937–42.
- Morris JS, Frith CD, Perrett DI, Rowland D, Young AW, Calder AJ, et al. A differential neural response in the human amygdala to fearful and happy facial expressions. *Nature* 1996; 383: 812–5.
- Mummery CJ, Patterson K, Wise RJ, Vandenberg R, Price CJ, Hodges JR. Disrupted temporal lobe connections in semantic dementia. *Brain* 1999; 122: 61–73.
- Mummery CJ, Patterson K, Price CJ, Ashburner J, Frackowiak RS, Hodges JR. A voxel-based morphometry study of semantic dementia: relationship between temporal lobe atrophy and semantic memory. *Ann Neurol* 2000; 47: 36–45.
- Neary D, Snowden JS, Gustafson L, Passant U, Stuss D, Black S, et al. Frontotemporal lobar degeneration: a consensus on clinical diagnostic criteria. [Review]. *Neurology* 1998; 51: 1546–54.
- Perry RJ, Hodges JR. Differentiating frontal and temporal variant frontotemporal dementia from Alzheimer's disease. *Neurology* 2000; 54: 2277–84.
- Perry RJ, Rosen HR, Kramer JH, Beer JS, Levenson RL, Miller BL. Hemispheric dominance for emotions, empathy and social behaviour: evidence from right and left handers with frontotemporal dementia. *Neurocase* 2001; 7: 145–60.
- Reed BR, Jagust WJ, Coulter L. Anosognosia in Alzheimer's disease: relationships to depression, cognitive function, and cerebral perfusion. *J Clin Exp Neuropsychol* 1993; 15: 231–44.
- Reitan RM. Validity of the Trail Making Test as an indicator of organic brain damage. *Percept Mot Skills* 1958; 8: 271–6.
- Rosen HJ, Gorno-Tempini ML, Goldman WP, Perry RJ, Schuff N, Weiner M, et al. Patterns of brain atrophy in frontotemporal dementia and semantic dementia. *Neurology* 2002; 58: 198–208.
- Schneider F, Grodd W, Weiss U, Klose U, Mayer KR, Nagele T, et al. Functional MRI reveals left amygdala activation during emotion. *Psychiatry Res* 1997; 76: 75–82.
- Scott SK, Young AW, Calder AJ, Hellawell DJ, Aggleton JP, Johnson M. Impaired auditory recognition of fear and anger following bilateral amygdala lesions. *Nature* 1997; 385: 254–7.
- Snowden JS, Bathgate D, Varma A, Blackshaw A, Gibbons ZC, Neary D. Distinct behavioural profiles in frontotemporal dementia and semantic dementia. *J Neurol Neurosurg Psychiatry* 2001; 70: 323–32.
- Sprengelmeyer R, Young AW, Calder AJ, Karnat A, Lange H, Homberg V, et al. Loss of disgust: perception of faces and emotions in Huntington's disease. *Brain* 1996; 119: 1647–65.
- Tanabe JL, Amend D, Schuff N, DiSclafani V, Ezekiel F, Norman D, et al. Tissue segmentation of the brain in Alzheimer disease. *AJNR Am J Neuroradiol* 1997; 18: 115–23.
- Watson C, Andermann F, Gloor P, Jones-Gotman M, Peters T, Evans A, et al. Anatomic basis of amygdaloid and hippocampal volume measurement by magnetic resonance imaging. *Neurology* 1992; 42: 1743–50.

Received January 14, 2002. Revised April 10, 2002.

Accepted May 13, 2002